

Cervical swelling in a dog

Contributors

Ignacio Amarillo-Gómez^{1,2}, Trinidad Artacho Burgos³, Jaume Alomar Huguet⁴, María Cuvertoret-Sanz⁴, Antonio Meléndez-Lazo¹

¹ T-Cito

² Universitat Autònoma de Barcelona

³ Hospital veterinario SOS Animal

⁴ IDEXX Laboratories

Ignacio Amarillo-Gómez: ignacio.amarillogomez@gmail.com

Specimen

Fine needle aspirate biopsy of the right cervical area.

Signalment

10-year-old male hunting dog.

History

The dog presented for swelling of the right cranial cervical area.

Clinical findings

Initial clinical examination revealed cervical swelling and pain upon palpation of the right retropharyngeal lymph node area. The rest of the general physical examination, hematology and serum biochemistry did not reveal any alterations.

Fine needle aspiration of the cervical region was performed, and samples were submitted to the laboratory for cytologic examination (Figures 1-2).

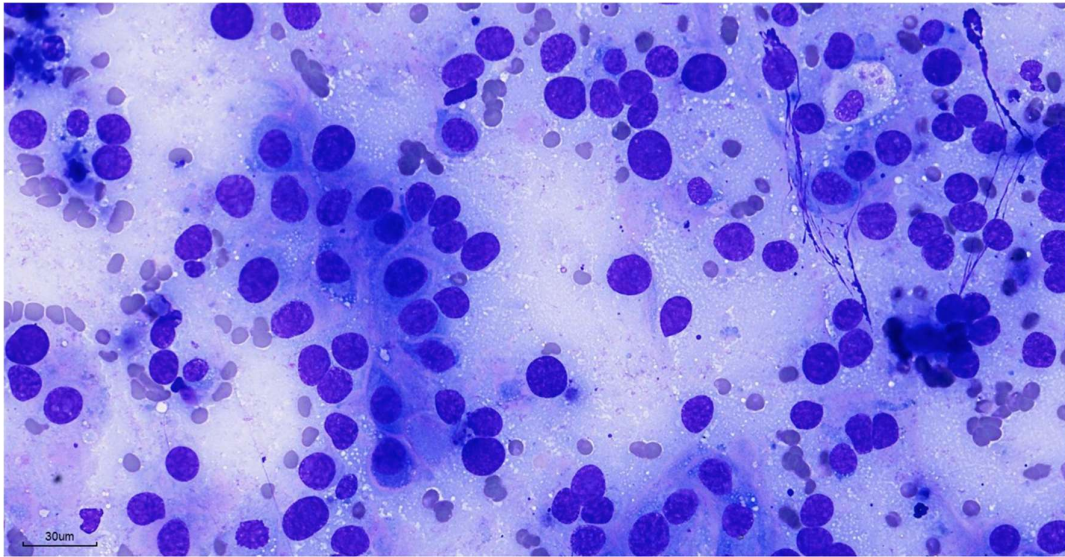


Figure 1. Fine needle aspirate of the cervical region (Modified Wright Giemsa) (100x)

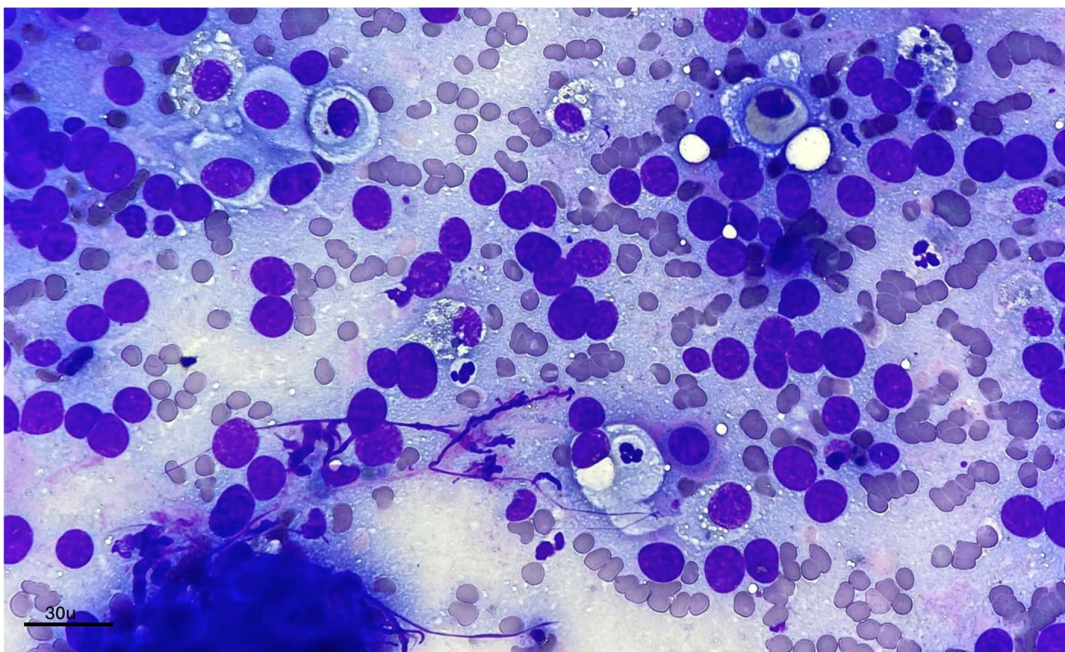


Figure 2. Fine needle aspirate of the cervical region, (Modified Wright Giemsa) (100x)

Questions

1. Based on the initial cytological findings, what are the main differential diagnoses for the observed cell population?
2. Considering the cytological interpretation and the location of the lesion, what would be the next recommended diagnostic steps to further investigate this case?